

Comparative Study Between Pedicled Groin Flap and Free Anterolateral Thigh Flap in Reconstruction of Complex Soft Tissue Hand Defects

Authors: Wael Ayad, **M.D.****; Gamal Ibrahim El-Habaa, **M.D.***; Emad Eldeen Mostafa Abdelhafez,, **M.D.***; Mostafa Saeed Abdeen, **M. Sc.***; Ola Ahmed Seif, **M.D.***; Ahmed Abdelrahim Shoulah, **M.D.***

** Department of General Surgery, Plastic Surgery Unit, Faculty of Medicine, Benha University, Egypt.*

***Plastic Surgery Department , Faculty of Medicine, Al Azhar University, Egypt.*

Abstract

Background: Soft tissue defects of the hand present a significant challenge in reconstructive surgery due to the hand's intricate anatomy and essential functional role. One of the main considerations in hand reconstruction is the choice of an appropriate flap. Among the various flaps used in hand reconstruction, the pedicled groin flap and the free anterolateral thigh flap have gained significant attention.

Aim of work: This study aimed to compare between pedicled groin flap and free anterolateral thigh flap in complex hand defects reconstructions regarding patient demographics, flap outcomes, complication rates, donor site morbidities and hospitalization period.

Material and methods: This multicenter prospective clinical trial was conducted from March 2021 to March 2022 on 20 patients with a clinical diagnosis of soft tissue defects of hand recruited from the Plastic Surgery Unit at General Surgery department, Faculty of Medicine, Benha University Hospital and Plastic Surgery department, Faculty of Medicine and Al Azhar University. Patients were divided into two groups, group (A) 10 patients who underwent pedicled groin flap and group (b): 10 patients who underwent free anterolateral thigh flap.

Results: There were 14 males and 6 female Their age ranged from 18-62 year .7 cases resulting from crush injury, 5 cases were due to burn and 8 cases were due to friction burn. Out of 10 patients who were reconstructed by pedicled groin flap, 1 patient (10%) was complicated by partial wound dehiscence and only 1 patient (10%) was complicated by infection. **out of 10 patients were reconstructed by The free anterolateral thigh flap 1 (10%) patient complicated by flap failure , 1 (10%) patient complicated by partial wound dehiscence and only 1 (10%) patient complicated by infection.**

Conclusion: The pedicled groin flap demonstrated favorable outcomes in older patients, leading to shorter operation times and hospital stays, making it a practical option for cases with relatively smaller defects. Conversely, the free anterolateral thigh flap proved suitable for complex large hand defects involving exposed tendons and joints, and it tended to be utilized more often in younger patients. **Patient satisfaction and complication rates were compared between the two groups.**

Keyword: Pedicled groin flap, Free ALT flap, hand reconstruction.

Ethical committee: Approval was obtained for this study from the Ethical Committee of Faculty of Medicine, Benha University. An informed written consent was obtained from all patients regarding surgical procedures and publication of their photos.

Diclosure: No conflict of interest

Corresponding author: Mostafa Saeed Abdeen, M. Sc; (mezro4ever@gmail.com)

Ethical Committee:

Introduction

The dorsum of the hand is a highly specialized region with thin, delicate skin and insufficient subcutaneous tissue. Typically, the dorsal surface of the hand is prone to a range of traumas (crush, degloving, hot press, and friction), resulting in exposed tendons and bone. ⁽¹⁾ These malformations necessitate early flap coverage to protect underlying vital tissues, preserve hand functions, and expedite healing. ⁽²⁾

When skin is grafted onto the paratenon or periosteum, it can lead to the formation of an unstable scar. Additionally, skin grafts cannot restore essential hand sensitivity. On the other hand, flaps encompass both the full thickness of skin and subcutaneous tissue, along with their dedicated blood supply. Consequently, they provide a more substantial and enduring skin covering, along with improved sensation, thanks to their own supply of cutaneous nerves. The utilization of local flaps is constrained to smaller areas. In cases involving significant tissue loss, where local and regional flaps are restricted by their size limitations and potential interference with the injury site, distant flaps may become necessary ⁽³⁾

Several flaps have been used to reconstruct and correct a variety of hand deformities. There are reversed flow flaps, such as the reversed radial forearm flap, that sacrifice a major vessel and reversed perforator forearm flaps that do not sacrifice vessels. ⁽⁴⁾ In addition, distant flaps are frequently employed to heal bigger wounds and provide a substantial volume of skin without causing morbidity to the damaged hand close to the donor location. Pedicle or free flaps may be utilized as remote flaps. ⁽⁵⁾

Among the several flaps utilized in hand reconstruction, the pedicled groin flap and the free anterolateral thigh flap have gained significant attention. The pedicled groin flap, which is built on the superficial circumflex iliac artery, is a fairly straightforward surgical technique that has been used to cover soft tissue in several body areas, including the hand. It provides optimum skin thickness and little morbidity at the donor site. ⁽⁶⁾

Conversely, the free anterolateral thigh flap, which relies on the lateral circumflex femoral artery system, has displayed remarkable versatility and flexibility when it comes to providing soft tissue coverage across diverse anatomical areas, including the hand. It boasts an extended

vascular pedicle, consistent anatomical characteristics, and access to a variety of tissues, including a sufficient amount of skin. These qualities render it an appealing choice for addressing intricate hand defects. Furthermore, the free anterolateral thigh flap can be employed as a flap that maintains sensory function and/or combines different tissue types, thereby further enhancing its potential for functional improvement in hand reconstruction. ⁽⁷⁾

Patients and methods

This multicenter **randomized prospective** clinical trial was conducted from March 2021 to March 2022 on 20 patients with a clinical diagnosis of soft tissue defects of hand recruited from the Plastic Surgery Unit at General Surgery department, Faculty of Medicine, Benha University Hospital and Plastic Surgery department, Faculty of Medicine, Al Azhar University. Patients were divided into two groups, group (A) 10 patients who underwent pedicled groin flap and group (b): 10 patients who underwent free anterolateral thigh flap.

Inclusion Criteria: Patients with clean wounds with healthy fractured, intact carpal or metacarpal bones with Exposed tendons, nerves, or vessels.

Exclusion Criteria: Patients with Infected wounds until they become clean, disruption of the vascular system of the upper limb, prior operations of the groin with impairment of the vasculature or uncontrolled chronic ill patients.

Both groups were compared regarding patient demographics, flap outcomes, complication rates, donor site morbidities and hospitalization period. Patients who were stable upon admission underwent wound debridement on the same day, with preparations for flap coverage initiated within a timeframe of 3 to 7 days.

Group (A): Pedicled Groin Flap:

Flap Marking: To delineate the flap, we first identified and marked key anatomical landmarks, including the inguinal ligament, femoral artery, and anterior superior iliac spine. Next, we drew a line approximately two finger breadths (about 2–3 cm) below the inguinal ligament in a parallel fashion to estimate the course of the superficial circumflex iliac artery (SCIA). The point of origin of SCIA was marked approximately 2.5 cm below the palpable pulse of the femoral artery. Patients were positioned in a supine manner with support under the buttock on the same side as the procedure. Ensuring that both the upper and lower borders of the flap aligned parallel to the inguinal ligament, we oriented the longitudinal axis of the flap to run parallel to the superficial circumflex iliac artery, which is situated partially above the inguinal ligament. Notably, one-third of the flap extended superior to the inguinal ligament, while the remaining two-thirds extended inferior to it (**Fig. 1**).

Flap Harvesting and Insetting: The dissection proceeded from the outer side to the inner side, reaching the deep aponeurosis. Deeper dissection was performed medially, particularly at the level of the sartorius muscle, to safeguard the integrity of the SCIA system. Immediate debulking was carried out, involving the removal of excess fat below the superficial fascia in patients with adipose tissue (**Fig. 2**). The donor site was closed using direct sutures after undermining the wound edges (**Fig. 3**). Subsequently, the flap was securely affixed to the hand defect using edge-to-edge non-absorbable sutures (**Fig. 4**).

Post-operative care: During the first three days, the flap was evaluated clinically by constantly observing its color, warmth, consistency, and capillary refill every six hours. This group of patients stayed in the hospital for five days. The flap was separated after 2-3 weeks and medial part of the flap was sutured (**fig. 5 & fig. 6**).

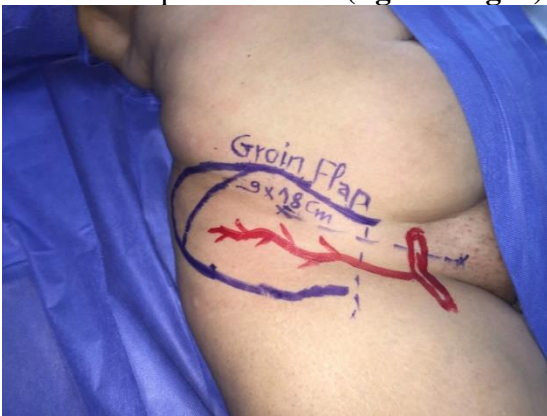
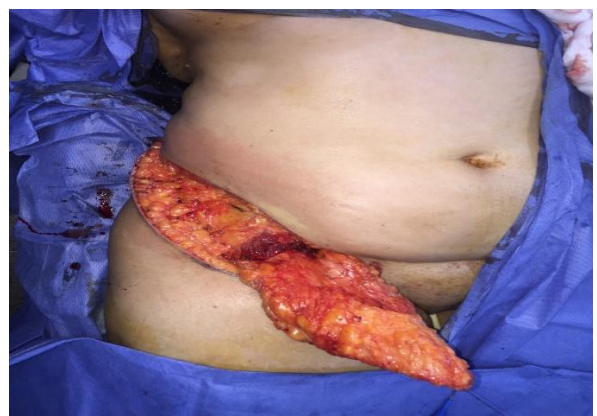
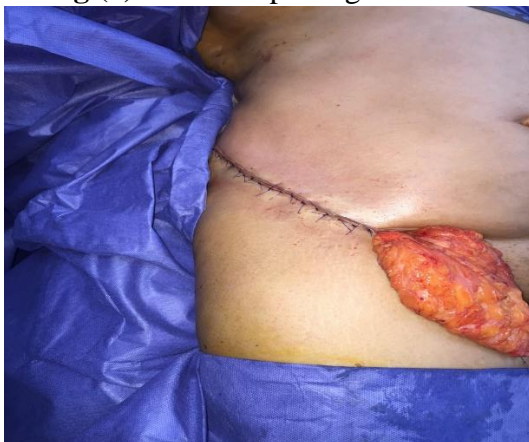Fig (1): Groin flap design.



Fig(2): Flap harvesting .



Fig(3): Direct closure of donor site.

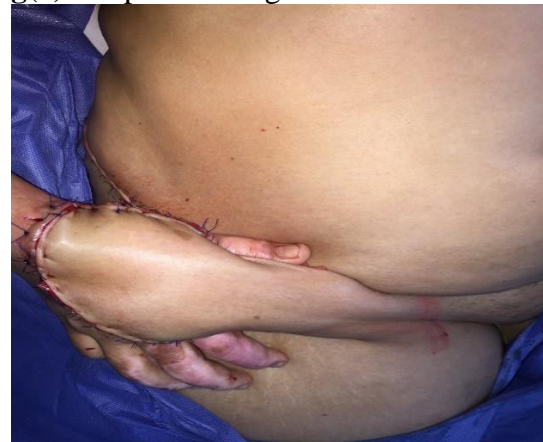
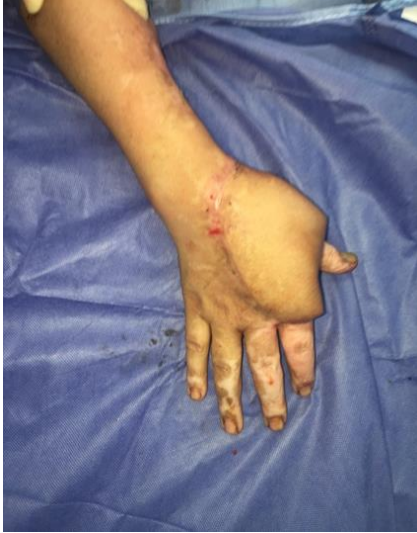
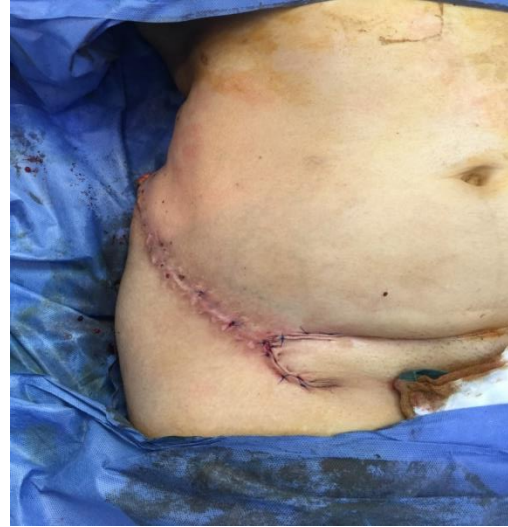Fig (4): Flap in sitting to hand defect.



Fig(5) : Separation of flap after 2-3 weeks



Fig(6) : Suturing of medial part of flap

Group (B): Anterolateral Thigh Flap

Two teams were beginning at the same time for preparation of the recipient site and elevation of the flap especially if preparation would take long time e.g. other include debridement of necrotic tissue after extensive post traumatic tissue loss.

Flap marking: In our patient cohort, we found that a Doppler audiometer sufficed, and there was no need for angiograms. The elevation of the flap requires a high level of expertise, especially in dealing with anatomical variations, and the surgical approach must be adaptable based on intraoperative findings. To determine the axis of the septum's surface between the rectus femoris and vastus lateralis muscles, we drew a line connecting the anterior superior iliac spine and the lateral patella. This line was then divided into thirds to guide the outlining of the flap. When identifying perforators, particular attention was given to the middle third, and the flap marking was centered around the perforator, taking into consideration the size of the defect (**fig 6**).

Flap harvesting: The patient was placed in a supine position, and the entire leg was included in the surgical field to allow for flexibility in limb placement and potential adjustments to the flap design. An incision was made over the rectus femoris muscle, maintaining a distance of 2–3 cm from the lateral intermuscular septum. To expose the vascular pedicle, the incision was extended upwards along the palpable groove between the rectus femoris and tensor muscle. The fascia along the rectus femoris muscle was incised, incorporating the intermuscular septum into the flap. By gently retracting the rectus femoris muscle medially, the vascular pedicle became visible. A vascular loop was created around the pedicle, and the intermuscular septum was

carefully cut at the lateral edge of the rectus muscle using scissors. The use of magnifying glasses is recommended to aid in the identification of perforators. Once the perforators, whether septocutaneous or myocutaneous, were identified and dissected distally, the vascular pedicle was exposed above the intermedius fascia and then ligated. After pinpointing the perforators, the entire skin island, along with the deep fascia, was circumferentially incised and secured at the anterior muscle border to prevent any stress on the perforators. Following the vascular pedicle distally, it was revealed on the surface of the vastus intermedius muscle by retracting the rectus femoris muscle. The neurovascular pedicle was completely dissected, while the fascia that constituted the intermuscular septum containing the perforating arteries was left intact. The components of the neurovascular pedicle were then detached, preparing the flap for subsequent microvascular transplantation (**fig 7**).

Direct closure was possible if the width of the skin paddle did not exceed 8–9 cm, split thickness graft was done for larger defects and suction drain was inserted in all case. The flap and soft tissues were kept moist all the time by irrigation also, Irrigation of the exposed vessels periodically with diluted lidocaine to keep them moist and minimize vasospasm.

Preparation of the recipient site: Maintaining bloodless field throughout the procedure had been done. Tourniquet for recipient vessel exposure was done (100 mmHg above systolic blood pressure), adequate padding, document pressure and time of application. Recipient vessels either radial artery , it is vena commitant and cephalic vein if defect in radial side or ulnar artery and basilic vein if defect near ulnar side (**fig 8**).

Free tissue transfer: Once flap was raised and isolated on supplying artery and veins securing the flap in place and taking a break for 20-30 mins was done and upon return; assessment of the flap color, capillary refill time and dermal bleeding. Dividing recipient vein, preparing its wall and irrigation with heparinized saline (5000 IU in 200 ml saline) was done. Making sure that the pedicle length was enough to reach to the area planned for anastomosis has been done before dividing of the flap.

Dividing the flap: liga clips proximally on artery and vein, distally liga clip the artery only (to mark it) by sharp scissors and Starting ischemia time. Preparing vessels wall was done through; clean cut, removal of adventitia, dilation, irrigation and placing within approximating double clamp (usually 3V). End to end anastomosis of the artery was done first then the vein, a second vein if available could be anastomosed for extra safety (**fig 9**).

Finally; in setting the flap, closure of the wounds, proper dressing without any pressure of flap and anastomosis, patient waking up pain free and without nausea with protection of the flap when moving the patient (**fig 10**).

Post-operative care: Close monitoring of the vital data of patient especially ABP for optimal tissue perfusion in ICU unit in the 1st 24hour. Urine output: 0.5- 1 ml/kg/hr. with avoidance overloading the circulation. Strict hand elevation was done. Post-operative good hydration of the patient by intravenous fluids and blood transfusion done if hemoglobin level below 7 gm/dl with

hematocrit level below 27 %. Post-operative medications included broad spectrum antibiotics, analgesics and low molecular weight (LMW) heparin daily throughout hospital stay.

Clinical assessment involved regular visual inspections of the flap, including the observation of its color, temperature, consistency, capillary refill, and frequent Doppler examinations of the pedicle. This assessment was conducted every two hours during the initial 24 hours to promptly detect any signs of ischemia or congestion. Subsequently, the frequency was reduced to every four hours on the following day and then extended to every eight hours until the fifth day. Vigilant monitoring was essential to promptly identify any hematoma formation, thereby preventing potential vascular compression.

Encouragement of oral fluids and stop fluids when appropriate was done. Adequate pain relief and antiemetics. Strictly no smoking, no caffeine for 2 weeks. Close surveillance of the drains, soiling of dressing, signs of hematoma under the flap or in the donor site and leg vascularity.

Patients stayed in hospital for 10-14 days and then were followed up at regular basis for 3-6 months. 2 stages flap debulking at 4 months interval was done in only 2 cases while rest of flap underwent immediate debulking.

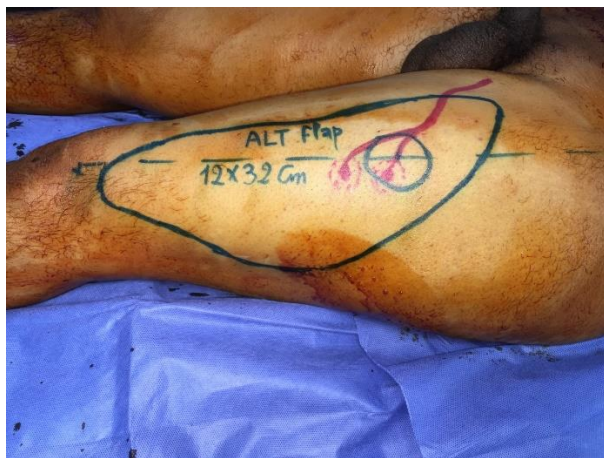

Fig. (6): ALT Flap design.

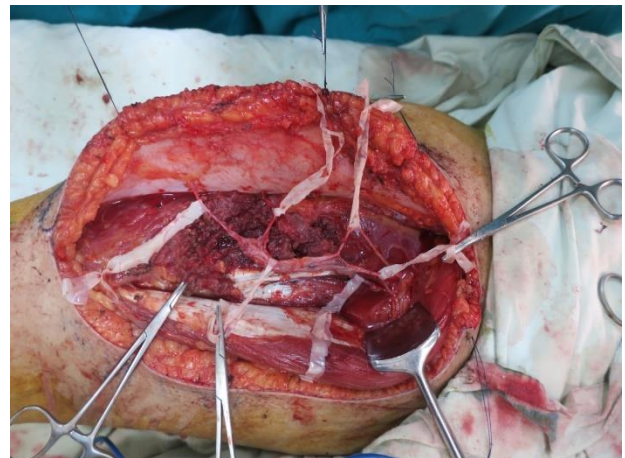


Fig. (7): Flap is isolated on vascular pedicle.

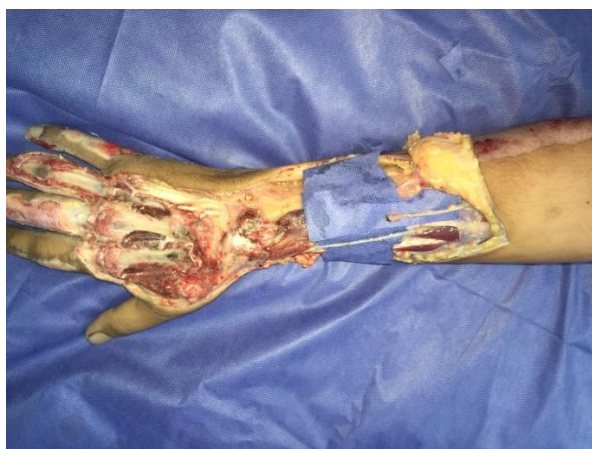

Fig. (8): Vessels in the recipient site.

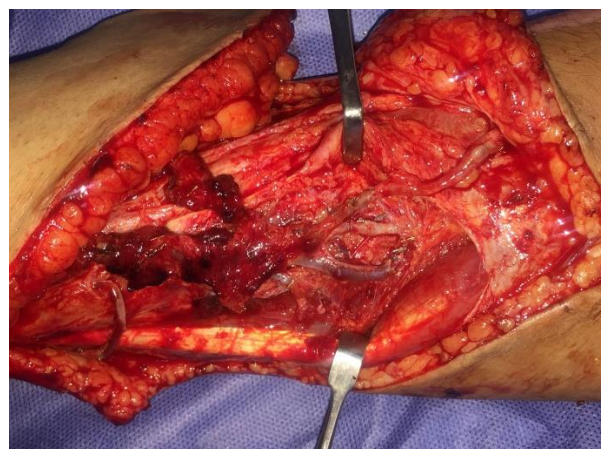


Fig. (9): Microvascular anastomosis.

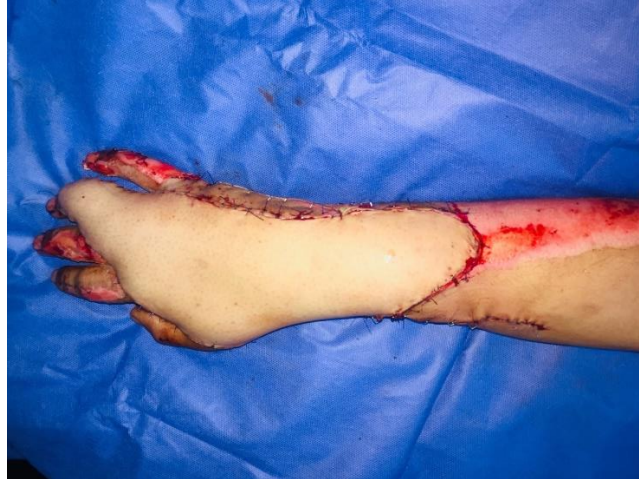

Fig.(10): In setting of flap .

Results

The patients who underwent pedicled groin flap procedures had ages spanning from 31 to 62 years, with an average age of 42.2 ± 10.17 years. Conversely, those who underwent free anterolateral thigh flap procedures were in the age range of 22 to 48 years, with an average age of 33.4 ± 8.36 years.

The age of patients who had pedicled groin flap was significantly higher than those who had free anterolateral thigh flap.

For those who had pedicled groin flap, 8 (80%) patients were males and 2 (20%) were females. And for those who had free anterolateral thigh flap, 6 (60%) patients were males and only 4 (40%) patient was female (**Table 1**).

Table 1: Baseline characteristics of the studied groups

		Pedicled groin flap (n =10)	Free anterolateral thigh flap (n =10)	P value
Age (year)	Mean ± SD	42.2 ± 10.17	33.4 ± 8.36	0.048*
	Range	31 - 62	22 - 48	
Sex	Male	8 (80%)	6 (60%)	0.628
	Female	2 (20%)	4 (40%)	

*Statistically significant as p value <0.05.

Regarding the presence of medical history in patients who underwent pedicled groin flap, 5 (50%) patients had hypertension, 4 (40%) patients had diabetes mellites, 1 (10%) patient had hepatic impairment, and 2 (20%) patients had heart diseases.

For those who underwent free anterolateral thigh flap, 2 (20%) patients had hypertension, 1 (10%) patient had diabetes mellites, and none of the patients had hepatic impairment or heart diseases.

There was no significant difference in medical history (hypertension, diabetes mellites, hepatic impairment, and heart diseases) between the studied groups(**Table 2**).

Table 2: Medical history in the studied groups.

	Pedicled groin flap (n =10)	Free anterolateral thigh flap (n =10)	P value
Hypertension	5 (50%)	2 (20%)	0.349
Diabetes mellites	4 (40%)	1 (10%)	0.303
Hepatic impairment	1 (10%)	0 (0%)	1.000
Heart diseases	2 (20%)	0 (0%)	0.474

*Statistically significant as p value <0.05.

Regarding the etiology of defect in patients who had pedicled groin flap, 3 (30%) patients had crush injury, 3 (30%) patients had burn injury, and 4 (40%) patients had friction injury.

For those who had free anterolateral thigh flap, 4 (40%) patients had crush injury, 2 (20%) patients had burn injury, and 4 (40%) patients had friction injury.

Regarding the exposed structures in patients who had pedicled groin flap, they were tendons in 6 (60%) patients, joints in 3 (30%) patients, and tendons and bones in only 1 (10%) patient.

And for those who had free anterolateral thigh flap, it was tendons in 5 (50%) patients, joint in 3 (30%) patients, and tendon and bones in 2 (20%) patients.

There was no significant difference in etiology and structures exposed between the studied groups (**Table 3**).

Table 3: Defect characteristics in the studied groups

		Pedicled groin flap (n =10)	Free anterolateral thigh flap (n =10)	P value
Etiology	Crush injury	3 (30%)	4 (40%)	0.843
	Burn injury	3 (30%)	2 (20%)	
	Friction injury	4 (40%)	4 (40%)	
Structures exposed	Tendon	6 (60%)	5 (50%)	0.809
	Joint	3 (30%)	3 (30%)	
	Tendon and bones	1 (10%)	2 (20%)	

*Statistically significant as p value <0.05.

The size of the defect in patients who received pedicled groin flap procedures varied, ranging from 10 to 15 cm, with an average measurement of 12.1 ± 1.85 cm. In contrast, for patients who underwent anterolateral thigh flap procedures, the defect size spanned from 18 to 29 cm, with a mean value of 24.1 ± 3.84 cm.

Regarding the width of the defect, patients who had pedicled groin flap procedures exhibited a range of 5 to 8 cm, with an average width of 5.9 ± 1.1 cm. Conversely, for those who underwent anterolateral thigh flap procedures, the defect width varied from 6 to 13 cm, with an average width of 8 ± 2.31 cm.

The length and width of defect in those who underwent pedicled groin flap was significantly lower than those who underwent anterolateral thigh flap(**Table 4**).

Table 4: Dimensions of defect in the studied groups

		Pedicled groin flap (n =10)	Free anterolateral thigh flap (n =10)	P value
Length of defect (cm)	Mean ± SD	12.1 ± 1.85	24.1 ± 3.84	<0.001*
	Range	10 - 15	18 - 29	
Width of defect (cm)	Mean ± SD	5.9 ± 1.1	8 ± 2.31	0.018*
	Range	5 - 8	6 - 13	

*Statistically significant as p value <0.05.

The flap length for patients who received pedicled groin flap procedures had a range of 10 to 18 cm, with an average length of 13.7 ± 2.58 cm. In contrast, for those who underwent anterolateral thigh flap procedures, the flap length varied between 20 to 32 cm, with a mean length of 26.1 ± 4.31 cm.

Concerning the flap width, patients who had pedicled groin flap procedures exhibited a width range of 5 to 9 cm, with an average width of 6.9 ± 1.6 cm. Conversely, for individuals who underwent anterolateral thigh flap procedures, the flap width ranged from 9 to 13 cm, with a mean width of 11.1 ± 1.73 cm.

The length and width of flap in those who underwent pedicled groin flap was significantly lower than those who underwent anterolateral thigh flap (**Table 5**).

Table 5: Dimensions of flap in the studied groups

		Pedicled groin flap (n =10)	Free anterolateral thigh flap (n =10)	P value
Length of flap (cm)	Mean ± SD	13.7 ± 2.58	26.1 ± 4.31	<0.001*
	Range	10 - 18	20 - 32	
Width of flap (cm)	Mean ± SD	6.9 ± 1.6	11.1 ± 1.73	<0.001*
	Range	5 - 9	9 - 13	

*Statistically significant as p value <0.05.

The operation time in patients who underwent pedicled groin flap ranged from 1.5 to 3 hours with a mean value of 2.19 ± 0.61 hours, and for those who underwent anterolateral thigh flap ranged from 5 to 8 hours with a mean value of 5.9 ± 1.1 hours.

The hospital stay in patients who underwent pedicled groin flap ranged from 2 to 3 days with a mean value of 2.5 ± 0.53 days, and for those who underwent anterolateral thigh flap ranged from 10 to 13 days with a mean value of 12 ± 1.05 days.

Operation time and hospital stay was significantly lower in patients who underwent pedicled groin flap compared to those who underwent free anterolateral thigh flap (**Table 6**).

Table 6 : Operation time and Hospital data in the studied groups

		Pedicled groin flap (n =10)	Free anterolateral thigh flap (n =10)	P value
Operation time	Mean \pm SD	2.19 \pm 0.61	5.9 \pm 1.1	<0.001*
	Range	1.5 - 3	5 - 8	
Hospital stay	Mean \pm SD	2.5 \pm 0.53	12 \pm 1.05	<0.001*
	Range	2 - 3	10 - 13	

*Statistically significant as p value <0.05.

Regarding complications of the flap in patients who underwent pedicled groin flap, partial wound dehiscence and infection each occurred in only 1 (10%) patient.

For patients who underwent free anterolateral thigh flap, flap failure, partial wound dehiscence, and infection each occurred in 1 (10%) patients.

Regarding patient satisfaction in patients who underwent pedicled groin flap, it was low in 1 (10%) patient, moderate in 5 (50%) patients, and high in 4 (40%) patients. In patients who underwent free anterolateral thigh flap, it was moderate in 2 (20%) patients, and high in 8 (80%) patients.

Patients' satisfaction and complications were insignificantly different between both groups (**Table 7**).

Table 7: Outcomes in the studied groups

		Pedicled groin flap (n =10)	Free anterolateral thigh flap (n =10)	P value
Complications of the flap	Flap failure	0 (0%)	1 (10%)	1.000
	Partial wound dehiscence	1 (10%)	1 (10%)	1.000
	Infection	1 (10%)	1 (10%)	1.000
Patient satisfaction	Low	1 (10%)	0 (0%)	0.164
	Moderate	5 (50%)	2 (20%)	
	High	4 (40%)	8 (80%)	

*Statistically significant as p value <0.05.

Regarding wound closure of donor site in patients who underwent pedicled groin flap, all patients had direct closure. For those who underwent free anterolateral thigh flap, direct wound closure occurred in 6 (60%) patients and graft closure occurred in 4 (40%) patients.

Regarding complications at donor site in patients who underwent pedicled groin flap, wound dehiscence occurred in 2 (20%) patients, infection, and hematoma each occurred in 1 (10%) patient. In patients who underwent free anterolateral thigh flap wound dehiscence occurred in 2 (20) patients and infection in 2 (20) patients.

Wound closure and complications at donor site were insignificantly different between both groups (**Table 8**).

Table 8: Donor site morbidity in the studied groups

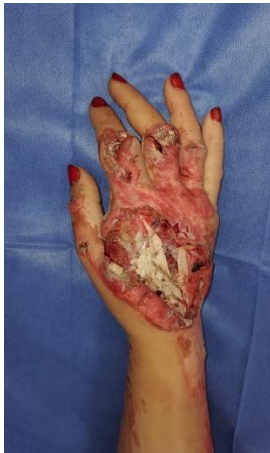		Pedicle groin flap (n =10)	Free anterolateral thigh flap (n =10)	P value
Wound closure	Direct	10 (100%)	6 (60%)	0.087
	Graft	0 (0%)	4 (40%)	
Complications at donor site	Wound dehiscence	2 (20%)	2 (20%)	1.000
	Infection	1 (10%)	2 (20%)	1.000
	Hematoma	1 (10%)	0 (0%)	1.000

*Statistically significant as p value <0.05.

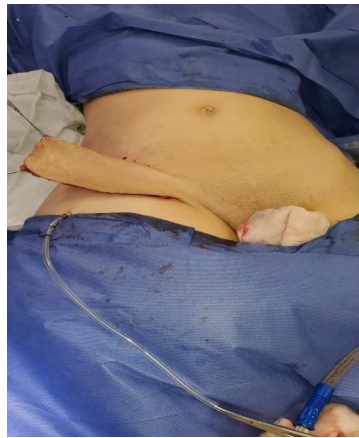
Case presentation

(A) Pedicle groin flap :

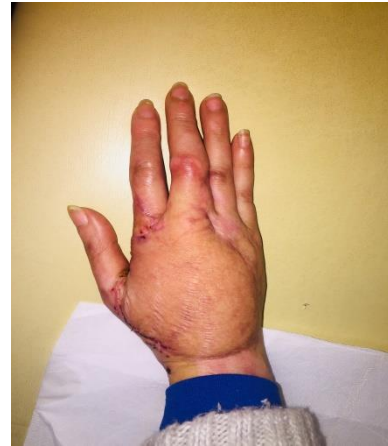Case (1)



Preoperative **Fig.(11)**

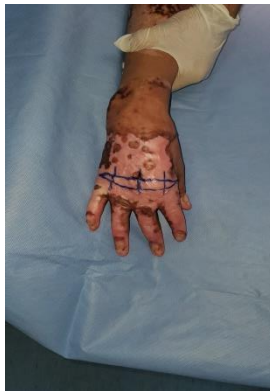

Intraoperative **Fig.(12)**

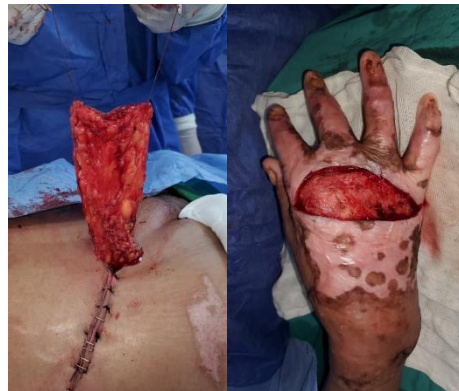

Postoperative **Fig.(13)**

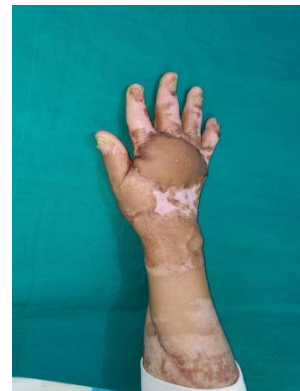Case (2)



Preoperative **Fig.(14)**



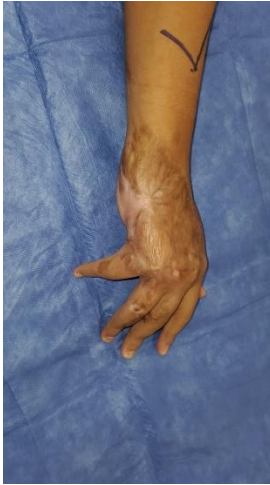Intraoperative **Fig.(15)**



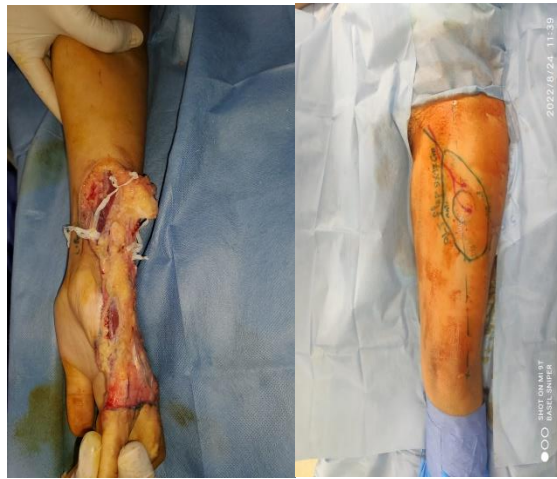Postoperative **Fig.(16)**

(B) Free anterolateral thigh flap :

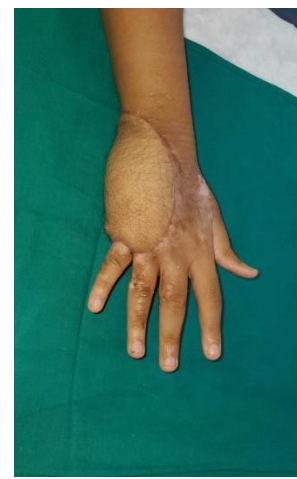Case (1)



Preoperative **Fig.(17)**

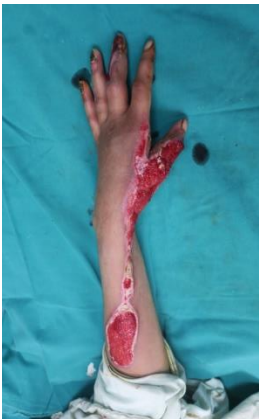

Intraoperative **Fig.(18)**

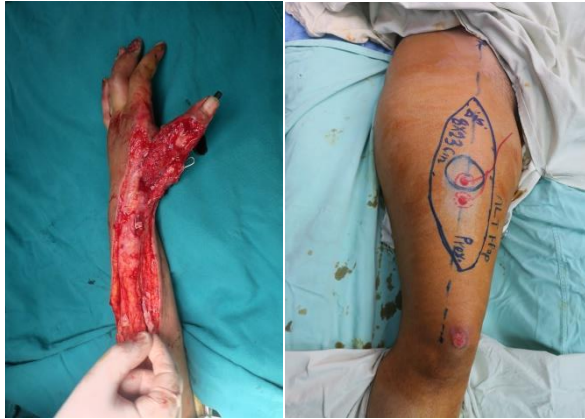

Postoperative **Fig.(19)**

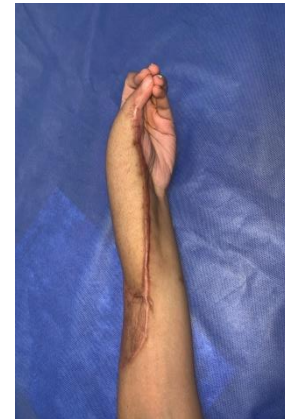Case (2)



Preoperative **Fig.(20)**



Intraoperative **Fig.(21)**



Postoperative **Fig.(22)**

Discussion

Restoration of hand function and aesthetics is essential for patients to regain their daily activities and quality of life. Over the years, advances in reconstructive techniques have provided plastic surgeons with an array of options for soft tissue coverage in hand defects.⁽⁸⁾

One of the main considerations in hand reconstruction is the choice of an appropriate flap. Flaps can be categorized as local flaps or free flaps, each with distinct advantages and limitations. Local flaps utilize adjacent tissues to cover the defect and are often preferred for smaller defects with sufficient tissue availability. However, local flaps may have limited reach and may not be suitable for larger and more complex defects.⁽⁹⁾

This study compared pedicled groin flap to free anterolateral thigh flap for complex hand defect reconstructions in two groups of 10 patients each.

The mean age of patients who had pedicled groin flap was 42.2 ± 10.17 and the age of those who had free anterolateral thigh flap was 33.4 ± 8.36 years. The age of patients who had pedicled groin flap was significantly higher than those who had free anterolateral thigh flap. For those who had pedicled groin flap, 8 (80%) patients were males and 2 (20%) were females. And for those who had free anterolateral thigh flap, 9 (90%) patients were males and only 1 (10%) patient was female. Sex was insignificantly different between both groups.

In the study conducted by Romana Parvin et al. (2021) on pedicle groin flap, the research revealed that the average age of participants was 30.68 ± 12.24 years, with a majority falling within the 20-29-year age bracket, and a predominance of males at 38 (63.3%).⁽³⁾

On the other hand, Moustafa Meky (2018) conducted a study on the versatility of the anterolateral thigh flap in dorsal hand reconstruction. In this study, there were 11 males (91.6%) and 1 female (8.4%), with ages ranging from 8 to 49 years (average age: 34.6 years).⁽¹⁰⁾

It is worth noting that the patients who underwent pedicled groin flap procedures tended to be significantly older compared to those who received free anterolateral thigh flap procedures. However, there was no statistically significant difference in terms of gender distribution between the two groups.

In agreement with our study (**Hussain et al., (2022)**. Found that the use of the pedicled groin flap in hand reconstruction more frequently in elderly patients.⁽¹¹⁾

Regarding the medical history, patients who underwent the pedicled groin flap had a higher prevalence of hypertension (50%), diabetes mellitus (40%), hepatic impairment (10%), and heart diseases (20%) compared to those who had the free anterolateral thigh flap 2 (20%) patients had hypertension, 1 (10%) patient had diabetes mellites, and none of the patients had hepatic impairment or heart diseases. Diabetes mellitus was significantly higher in patients who underwent pedicled groin flap.

Kayano et al. (2012) found that the pedicled groin and free ALT flap groups had similar proportions of patients with diabetes and hypertension. However, heart disease was reported in only 1 patient from the Pedicled groin flap group and none from the Free ALT flap group.⁽¹²⁾

In terms of etiology and exposed structures, the etiology of the defect differed between the two groups. For those who had free anterolateral thigh flap, 4 (40%) patients had crush injury, 2 (20%) patients had burn injury, and 4 (40%) patients had friction injury. Regarding the exposed structures in patients who had pedicled groin flap, they were tendons in 6 (60%) patients, joints in 3 (30%) patients, and tendons and bones in only 1 (10%) patient. And for those who had free

anterolateral thigh flap, it was tendons in 5 (50%) patients, joint in 3 (30%) patients, and tendon and bones in 2 (20%) patients. There was no significant difference in etiology and structures exposed between the studied groups.

Du et al. (2022) found that in patients who underwent the free anterolateral thigh flap, crush injury was the prevailing cause (60%), while patients who received the other flap were more commonly affected by friction injury (40%). Furthermore, the free anterolateral thigh flap group exhibited a significantly higher number of patients with exposed tendons and joints compared to the other group. ⁽¹³⁾

The length and width of defect in those who underwent pedicled groin flap was significantly lower than those who underwent anterolateral thigh flap.

Romana Parvin, et al. (2021) showed in their study that the mean length and width of the wound in patient whose underwent pedicled groin flap in hand reconstruction was 8.15 (± 2.60) cm and 6.00 (± 1.86) cm respectively. ⁽³⁾

The length and width of flap in those who underwent pedicled groin flap was significantly lower than those who underwent anterolateral thigh flap.

Consistent with our research findings, Romana Parvin et al. (2021) reported in their study that the average dimensions of the flap were 8.97 cm (± 2.82 cm) in length and 6.30 cm (± 1.83 cm) in width. The maximum observed flap length in their study was 18 cm, and the maximum flap width reached 10 cm. ⁽³⁾

Similarly, in the study conducted by MOUSTAFA MEKY (2018), the size of the free ALT flap ranged from 5-9 cm, with a width-to-length ratio spanning from 6 to 14 cm. ⁽¹²⁾

Regarding the operation time and hospital stay, the operation time in patients who underwent pedicled groin flap ranged from 1.5 to 3 hours with a mean value of 2.19 ± 0.61 hours, and for those who underwent anterolateral thigh flap ranged from 5 to 8 hours with a mean value of 5.9 ± 1.1 hours.

The hospital stays in patients who underwent pedicled groin flap ranged from 2 to 3 days with a mean value of 2.5 ± 0.53 days, and for those who underwent anterolateral thigh flap ranged from 10 to 13 days with a mean value of 12 ± 1.05 days.

Operation time and hospital stay was significantly lower in patients who underwent pedicled groin flap compared to those who underwent free anterolateral thigh flap.

In line with our findings, **Kayano et al. (2012)** reported that the reconstructive time, defined as the time taken for the surgery in minutes, was longer for the Free ALT flap group, with a mean of 392 minutes compared to 105 minutes for the Pedicled groin flap group. ⁽¹¹⁾

Moreover, **Du et al. (2022)** found the free ALT group had longer operation and hospitalization time ($P < 0.05$). ⁽¹²⁾

Regarding complications of the flap in patients who underwent pedicled groin flap, partial wound dehiscence and infection each occurred in only 1 (10%) patient. For patients who underwent free anterolateral thigh flap, flap failure, partial wound dehiscence, and infection each occurred in 1 (10%) patient.

Regarding patient satisfaction in patients who underwent pedicled groin flap, it was low in 1 (10%) patient, moderate in 5 (50%) patients, and high in 4 (40%) patients. In patients who underwent free anterolateral thigh flap, it was moderate in 2 (20%) patients, and high in 8 (80%) patients.

There was no significant difference in patient satisfaction and complications between both groups.

In their study, **Romana et al.** found that approximately 10% of patients experienced marginal necrosis in the groin flap, and only 2% faced a complete loss of the groin flap. In contrast, the majority, which accounted for 86.67% of patients, encountered no complications related to the flap. Regarding the results of the reconstruction, 83.3% of patients achieved excellent wound coverage, 13.3% experienced satisfactory wound coverage, and only 3.3% had poor wound coverage. ⁽³⁾

Similarly, **Moustafa Meki**, in alignment with our findings, reported in his study that among the 12 free ALT flaps harvested, only one flap, which was used for post-burn reconstruction, experienced complete failure due to vein thrombosis, despite exploratory and revision attempts. Additionally, two flaps, one for traumatic cases and one for post-burn reconstruction, developed partial flap necrosis. One of these cases healed through secondary intention, while the other required skin grafting. ⁽¹⁰⁾

Regarding wound closure of donor site in patients who underwent pedicled groin flap, all patients had direct closure. For those who underwent free anterolateral thigh flap, direct wound closure occurred in 6 (60%) patients and graft closure occurred in 4 (40%) patients.

Regarding complications at donor site in patients who underwent pedicled groin flap, wound dehiscence occurred in 2 (20%) patients, infection, and hematoma each occurred in 1 (10%) patient. Among the patients who received free anterolateral thigh flap procedures, 2 out of 10 (20%) experienced wound dehiscence, and an additional 2 out of 10 (20%) developed infections. Notably, there was no statistically significant distinction in wound closure rates or the occurrence of complications at the donor site between the two groups.

In agreement with our study **Romana Parvin, et al.** showed in their study that all patients who underwent pedicled groin flap had direct closure of donor site and only 10% had wound dehiscence. ⁽³⁾

In line with this, **Moustafa Meky's** study demonstrated that all donor sites for the flaps were closed directly without requiring skin grafts. Only one case experienced donor site morbidity in the form of wound dehiscence, while the remaining cases achieved complete healing. ⁽¹⁰⁾

Conclusion

Hand defects impose challenges for surgeons during reconstruction and various pedicled and free flaps are described for these defects. Groin flap has an important place in the reconstruction of hand defects especially in small defects in patients with co-morbidity and characterized by less time operation, less hospital stays and easy to apply option but in the same it is two staged operations with long time recovery.

Free anterolateral thigh flap is an excellent option in patient with large and complex soft tissue hand defects especially in young patients with two favorable advantages as it is single stage operation and easy conformability to complex curved surfaces of the hand but at the same time require high experience in micro vascular surgery and take longer operation time and hospital stay.

References

1. Adani R. Dorsal hand coverage. BMC Proc. 2015;9(Suppl 3):A59. doi:10.1186/1753-6561-9-S3 A59
2. Khan MM, Yaseen M, Bariar LM, Khan SM. Clinical study of dorsal ulnar artery flap in hand reconstruction. Indian J Plast Surg. 2009;42(1):52-57. doi:10.4103/0970-0358.53012
3. Romana Parvin1*, Mohd Fazle Rubby2, Mohammad Abul Kalam Azad3, Md. Toriqul Islam4, Md Shahidul Islam Farhad5. "Groin Flap" for Reconstruction of Defects on Dorsum of the Hand. Annals of International Medical and Dental Research E-ISSN: 2395-2822 | P-ISSN: 2395-2814 2021
4. Bocchi A, Quarta L, Castri AD, Boschi E, Caleffi E. Reverse perforator flaps in the reconstruction of the hand. our clinical experience. The Open Orthopaedics Journal. 2015;9(1):1.

5. Takahashi M, Kasai T, Nishisho T, Takai M, Endo H, Hirose T, et al. Reverse adipofascial flap after resection of a malignant perineurioma of the forearm. *Orthopedics*. 2014;37(7):e661-4. doi: 10.3928/01477447-20140626-65.
6. Liu, X., Huo, D. & Wu, G. 2021. Deep Inferior Epigastric Flap Combined Bilateral-Anterolateral Thigh Flap for the Coverage of Both Lower Extremity Soft-Tissue Defect: A Case Report and a Literature Review. *Clin Cosmet Investig Dermatol*, 14, 153-161.
7. Sagheer, S. H. & Reschly, W. 2019. A case report of aberrant vascular anatomy of the anterolateral thigh flap. *Cureus*, 11.
8. Cormack G (1992). Anterolateral thigh flap: technical tip to facilitate elevation. *British Journal of Plastic Surgery*, 45: 74.
9. **Benanti, E., De Santis, G., Leti Acciaro, A., Colzani, G., Baccarani, A. & Starnoni, M. 2020.** Soft tissue coverage of the upper limb: A flap reconstruction overview. *Ann Med Surg (Lond)*, 60, 338-343.
10. **Moustafa Meki** .2018 .Versatility of Anterolateral Thigh Flap in Dorsal Hand Reconstruction Egypt, *J. Plast. Reconstr. Surg.*, Vol. 42, No. 2, July: 311-315
11. **Hussain, T., Khan, F. H., Rahman, O. U. & Beg, M. S. A.** 2022. Superficial Circumflex Iliac Artery Free Flap for Coverage of Hand Injuries. *Cureus*, 14, e31520.
12. **Kayano, S., Sakuraba, M., Miyamoto, S., Nagamatsu, S., Taji, M., Umezawa, H., et al.** 2012. Comparison of pedicled and free anterolateral thigh flaps for reconstruction of complex defects of the abdominal wall: review of 20 consecutive cases. *J Plast Reconstr Aesthet Surg*, 65, 1525-9.
13. **Du, S., Wei, S., Zhang, H., Li, P., Ni, X., Hua, F., et al.** 2022. Comparison of "complications" and functional outcome of anterolateral thigh flap and sural neurofasciocutaneous flap for foot and ankle reconstruction: A single center cohort study. *Injury*, 53, 3843-3848.